

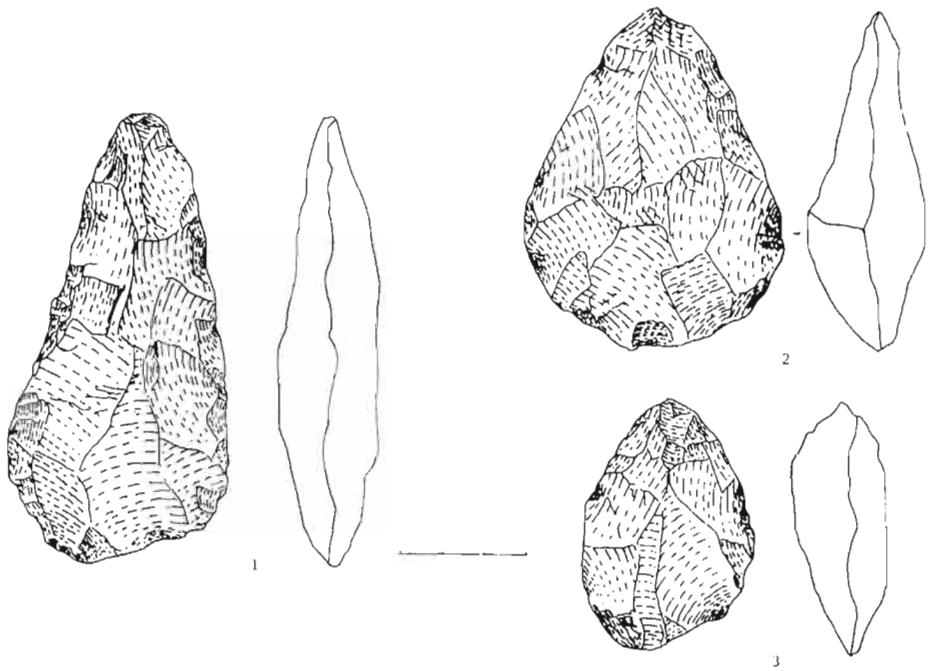Figura 4. 1. Bifaz subtriangular; 2-3. Bifaz amigdalóide corto.

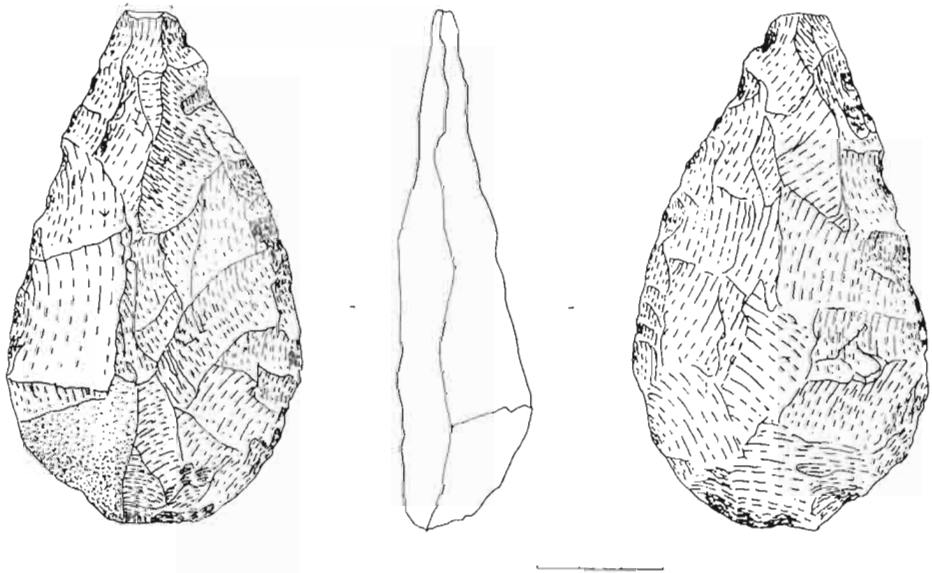


Figura 5. Bifaz cordiforme alargado.